



# ECG Diagnosis With the **SONOPLUS™ 3000-DS**

## **Clinical Validation** **A Newsletter Service Provided by** **Pulsonic AG Medical Technologies,**

The SONOPLUS 3000-DS is a mobile, high performance and high quality electrocardiograph-stethoscope combination product designed and manufactured by PULSONIC AG, Switzerland.

---

The following ECG tracings have been recorded by cardiologist Fulvio Bomio, MD, at the Cardiocentro Ticino in Lugano, Switzerland. Dr. Bomio has been working with the SONOPLUS 3000-DS since September 2005. For each patient, a SONOPLUS ECG tracing was obtained shortly after the recording of a 12-lead ECG.



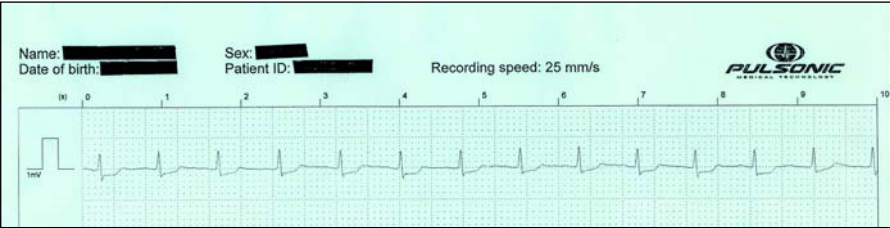
Dr. Bomio states: *"I think that the SONOPLUS is a very useful companion for clinical patient evaluation".*

Dr. Fulvio Bomio, May 2006  
with the SONOPLUS 3000-DS

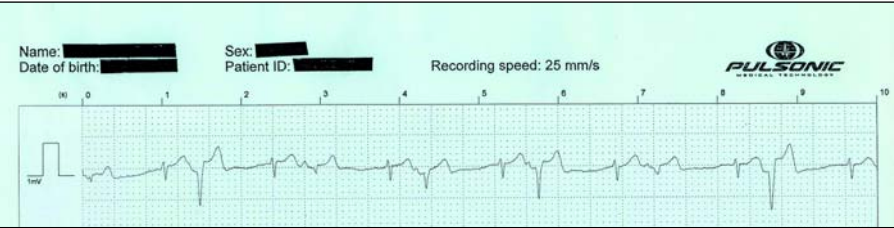Pulsonic AG has provided Dr. Bomio with a SONOPLUS 3000-DS. Dr. Bomio has no financial interests in Pulsonic AG.

| ECG No.              | Age (y) | Sex (M/F)  | SONOPLUS Lead | Relevant Diagnosis                  |
|----------------------|---------|--|---------------|-------------------------------------|
| 1                    | 67      | F  | II            | Two-vessel coronary artery disease. |
| <b>ECG Diagnosis</b> |         | Anteroseptal myocardial infarction.  |               |                                     |
| <b>Note</b>          |         | The SONOPLUS lead II indicates the presence of anterior myocardial infarction as ST segment depression, compared to the ST segment elevation of the precordial leads V1 and V2 in the 12 lead ECG. |               |                                     |

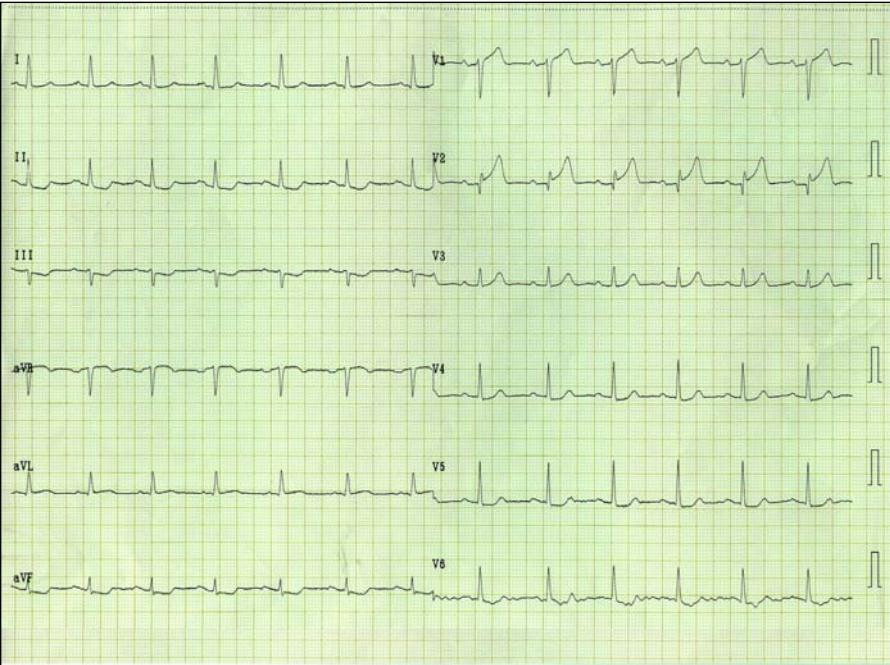
| ECG No.              | Age (y) | Sex (M/F)  | SONOPLUS Lead | Relevant Diagnosis  |
|----------------------|---------|--|---------------|---|
| 2                    | 71      | F  | aVF           | Coronary artery disease<br>Severe valvular aortic stenosis. |
| <b>ECG Diagnosis</b> |         | Supraventricular extrasystoles with aberrant atrio-ventricular conduction. |               |   |



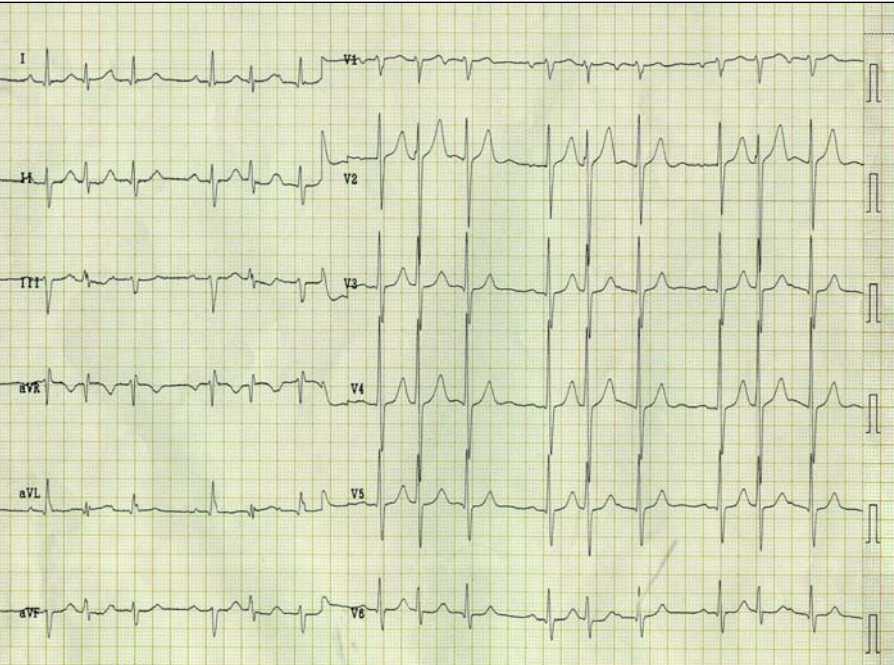
SONOPLUS ECG tracing



SONOPLUS ECG tracing



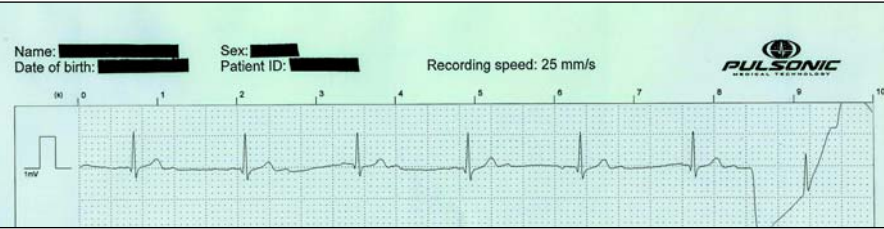
12 lead ECG tracings



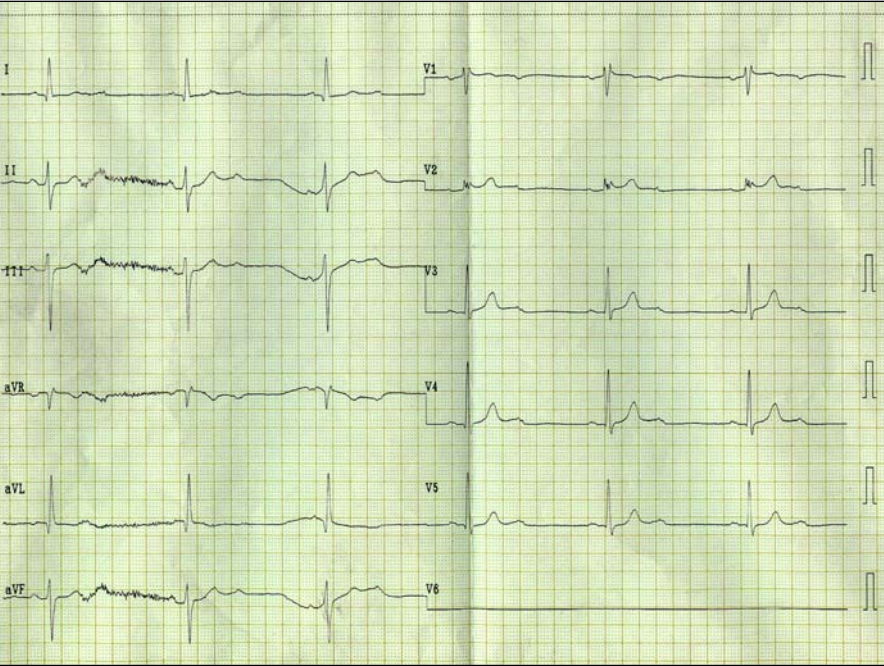
12 lead ECG tracings



| ECG No.              | Age (y) | Sex (M/F)  | SONOPLUS Lead | Relevant Diagnosis   |
|----------------------|---------|--|---------------|--|
| 3                    | 84      | M  | I             | Hypertensive cardiomyopathy. 2 <sup>nd</sup> degree atrio-ventricular block with 2:1 atrio-ventricular conduction. Syncopal episode. |
| <b>ECG Diagnosis</b> |         | Syncope with 2nd degree atrio-ventricular block. |               |  |

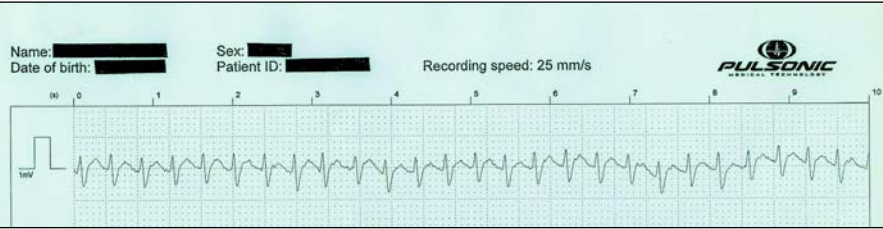


SONOPLUS ECG tracing

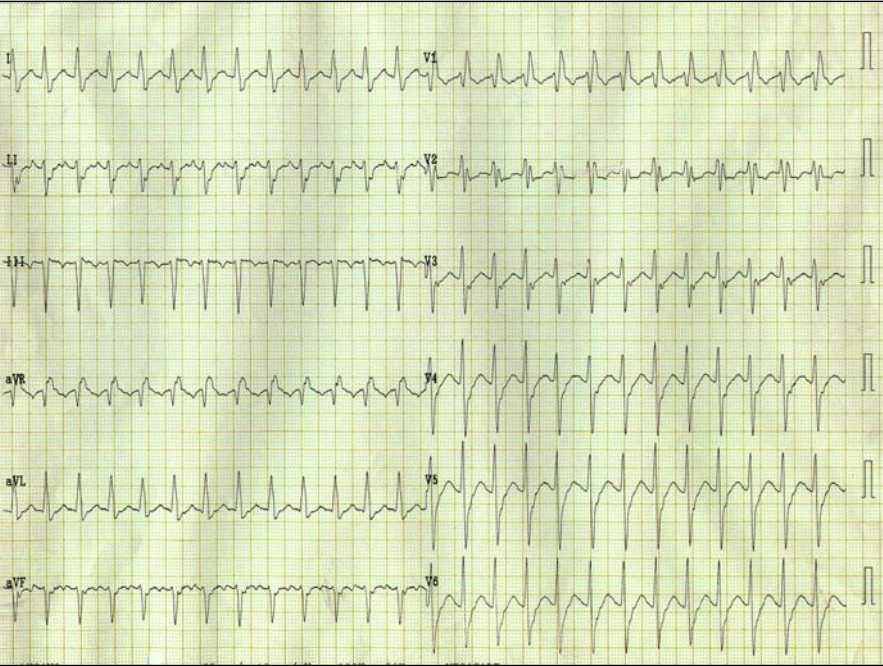

12 lead ECG tracings

| ECG No.              | Age (y) | Sex (M/F)  | SONOPLUS Lead | Relevant Diagnosis  |
|----------------------|---------|--|---------------|---|
| 4                    | 73      | M  | I             | Ischemic and valvular cardiomyopathy with severe mitral regurgitation and moderate aortic stenosis. |
| <b>ECG Diagnosis</b> |         | Atrial flutter with 2:1 atrio-ventricular conduction and right bundle branch block (RBBB). |               |   |



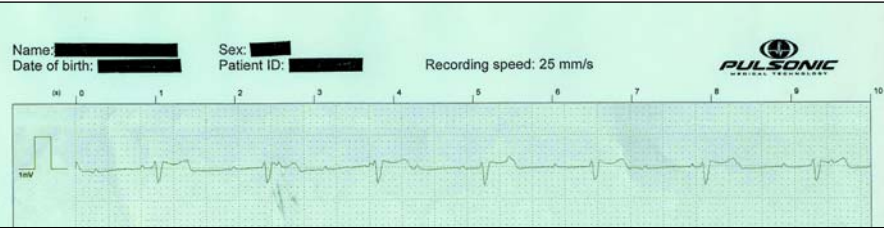
SONOPLUS ECG tracing



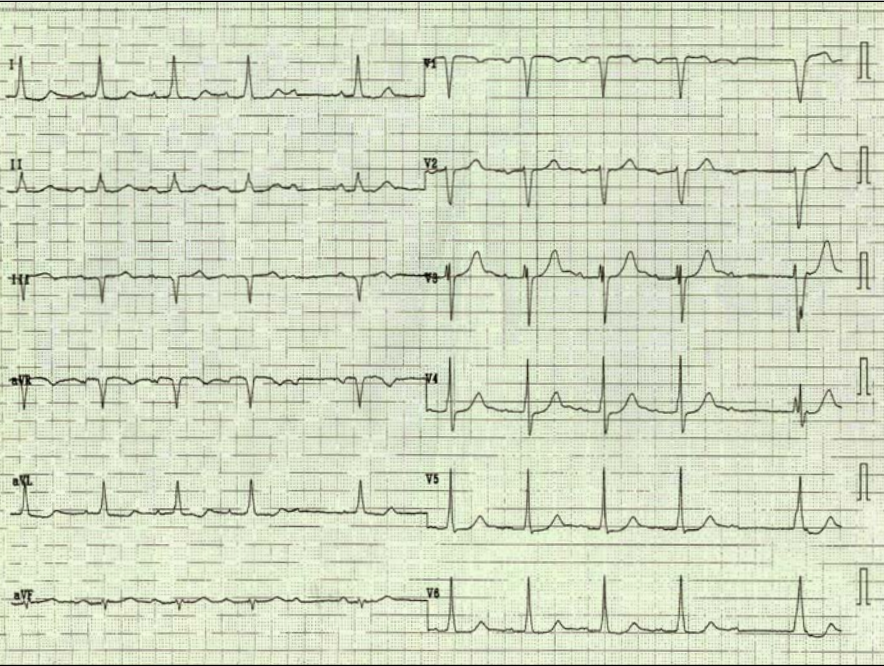
12 lead ECG tracings



| ECG No.              | Age (y)   | Sex (M/F) | SONOPLUS Lead | Relevant Diagnosis                        |
|----------------------|---|-----------|---------------|---|
| 5                    | 84  | M         | aVF           | Hypertensive and coronary cardiomyopathy. |
| <b>ECG Diagnosis</b> | Sinus rhythm with 2 <sup>nd</sup> degree atrio-ventricular block type Wenckebach.   |           |               |   |
| <b>Note</b>          | The SONOPLUS lead aVF indicates the presence of a 3 <sup>rd</sup> degree atrio-ventricular block with atrio-ventricular dissociation. |           |               |   |

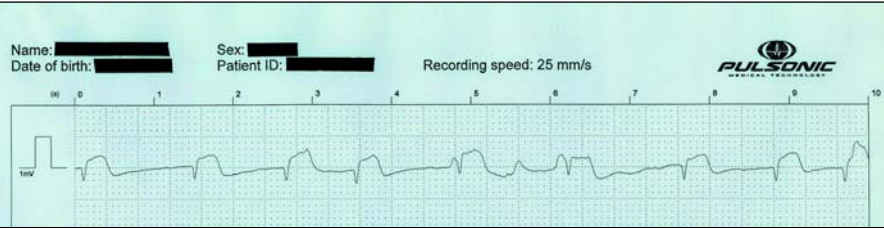


SONOPLUS ECG tracing

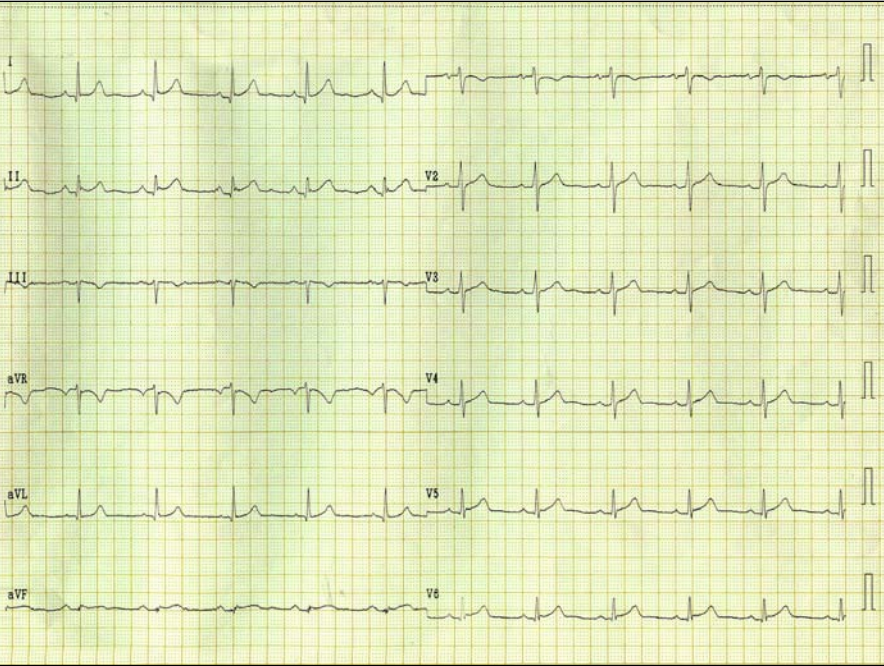


12 lead ECG tracings

| ECG No.              | Age (y)   | Sex (M/F) | SONOPLUS Lead | Relevant Diagnosis                    |
|----------------------|---|-----------|---------------|---------------------------------------|
| 6                    | 63  | F         | II            | Acute inferior myocardial infarction. |
| <b>ECG Diagnosis</b> | Suspicion of acute inferior myocardial infarction.  |           |               |                                       |
| <b>Note</b>          | The SONOPLUS lead II was recorded prior to the 12 lead ECG and indicates the presence of an acute inferior myocardial infarction with probable 3 <sup>rd</sup> degree atrio-ventricular block. By the time the 12 lead ECG was recorded, the patient had been treated with nitrates followed by partial resolution of the chest pain. |           |               |                                       |



SONOPLUS ECG tracing

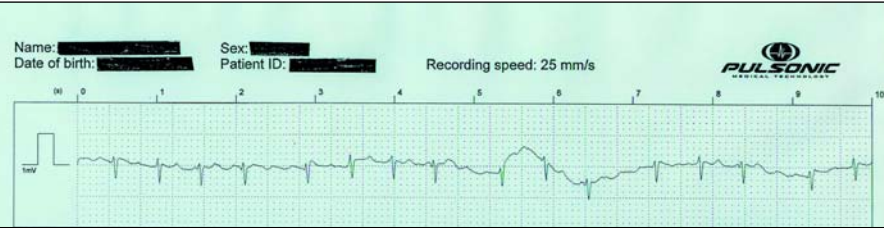


12 lead ECG tracings

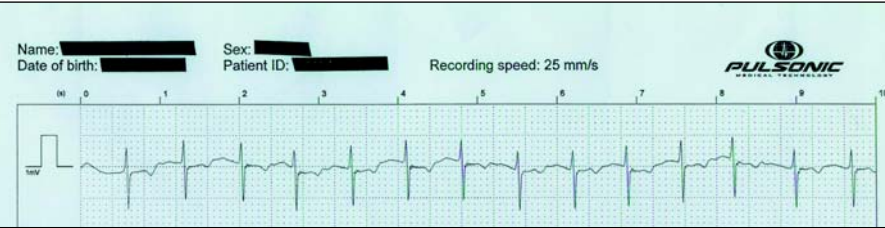


| ECG No.       | Age (y) | Sex (M/F)  | SONOPLUS Lead | Relevant Diagnosis  |
|---------------|---------|--|---------------|---|
| 7             | 68      | M  | III           | Valvular cardiomyopathy.<br>Status post coronary artery bypass graft.<br>Arterial hypertension. |
| ECG Diagnosis |         | Atrial flutter with variable atrio-ventricular conduction. |               |   |

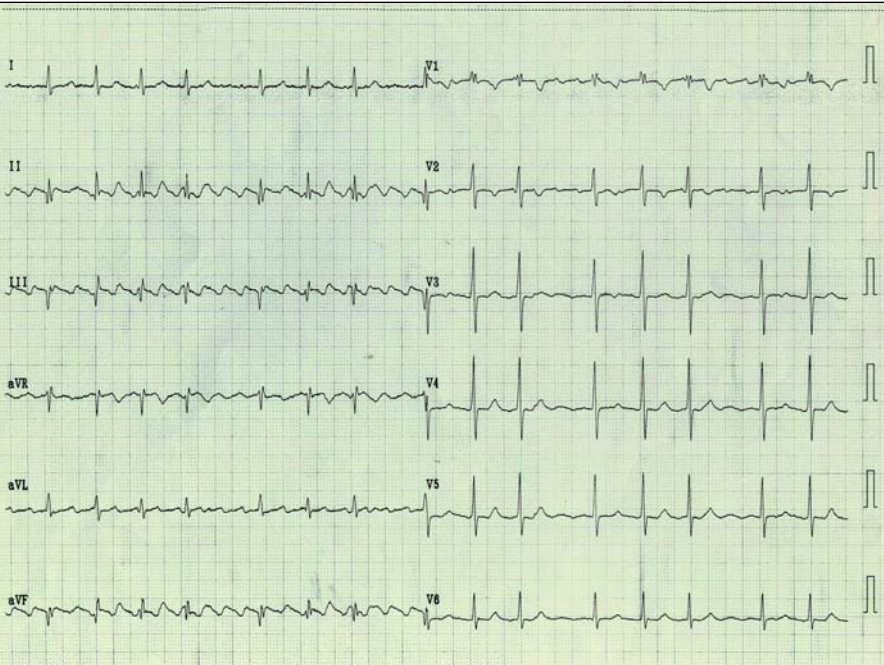
| ECG No.       | Age (y) | Sex (M/F)                        | SONOPLUS Lead | Relevant Diagnosis                                  |
|---------------|---------|----------------------------------|---------------|---|
| 8             | 80      | F                                | II            | Hypertensive, valvular and coronary cardiomyopathy. |
| ECG Diagnosis |         | Normocardic atrial fibrillation. |               |   |



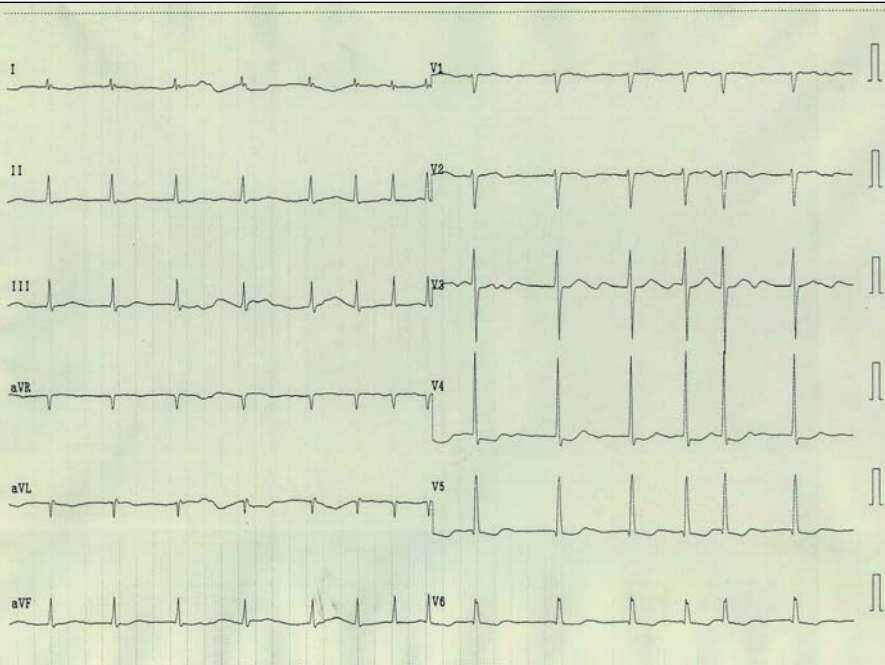
SONOPLUS ECG tracing



SONOPLUS ECG tracing



12 lead ECG tracings



12 lead ECG tracings